

SUPPLEMENTARY DATA

***Listeria monocytogenes* Endocarditis: Case Report, Review of the Literature, and Laboratory Evaluation of Potential Novel Antibiotic Synergies**

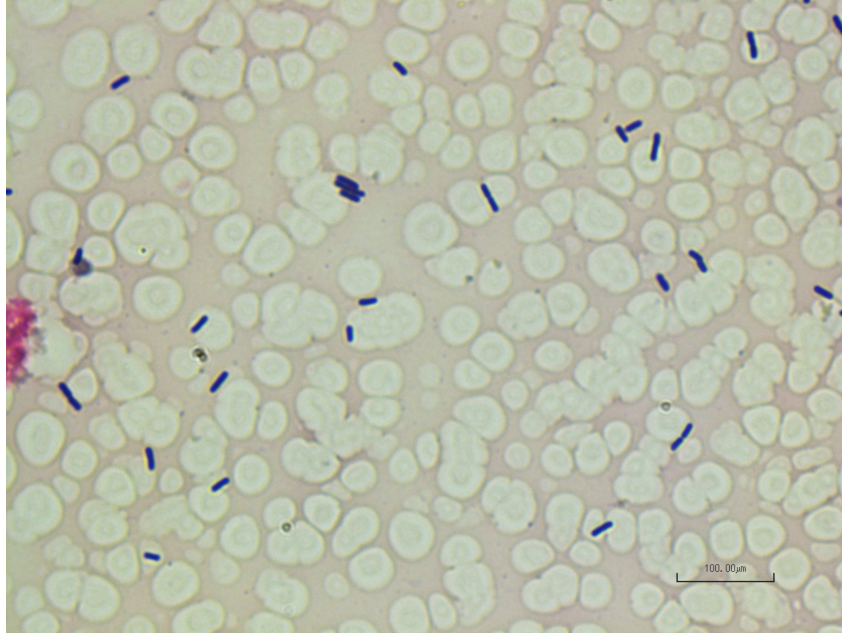
Monika Kumaraswamy, Carter Do, George Sakoulas, Poochit Nonejuie, Guan Woei Tseng, Helen King, Nicholas Wettersten, Joshua Fierer, Joe Pogliano and Victor Nizet

Contents:

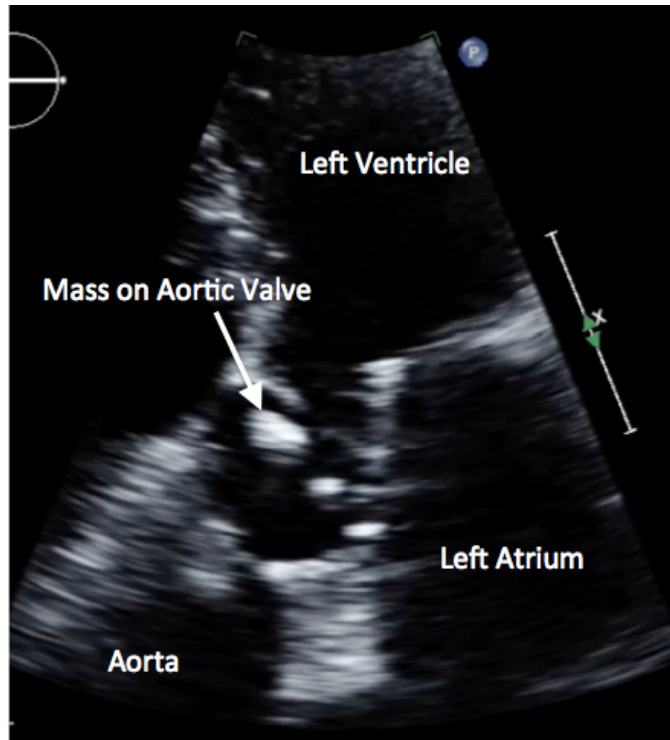
Supplementary Figure 1

Supplementary Figure 2

References For Table 1



Supplementary Figure 1. Gram stain of blood culture illustrating Gram-positive rods.



Supplementary Figure 2. Echocardiography revealing an aortic valve mass (1.25 cm x 1.0 cm).

REFERENCES FOR TABLE 1

- [1] Hoeprich PD, Chernoff HM. Subacute bacterial endocarditis due to *Listeria monocytogenes*. *Am J Med* 1955;19:488–94.
- [2] Seeliger H. *Listeriosis*, Hafner, New York, 1961.
- [3] Baker CC, Felton FG, Muchmore HG. *Listeriosis*: report of 5 cases. *Am J Med Sci* 1961;241:739–43.
- [4] Brecht W, Oesterle D. [On endocarditis listeriosa]. *Chemotherapia (Basel)* 1962;4:573–9.
- [5] Simpson JF, Leddy JP, Hare JD. *Listeriosis* complicating lymphoma. Report of four cases and interpretive review of pathogenetic factors. *Am J Med* 1967;43:39–49.
- [6] Buchner LH, Schneierson S. Clinical and laboratory aspects of *Listeria monocytogenes* infections. With a report of ten cases. *Am J Med* 1968;45:904–21.
- [7] Elston HR, Zencka AE, Sketch MH. *Listeria monocytogenes* endocarditis: a clinical and bacteriological report. *Arch Intern Med* 1969;124:488–91.
- [8] Goasguen J, Costeseque P, Jossierand C, Oddou A, Paillet R, Sagnet H. [Septicemia with endocarditis caused by *Listeria monocytogenes* in a 10-year-old Biafran child]. *Med Trop (Mars)* 1969;29:699–701.
- [9] Latour H, Puech P, Balmes P, Cabasson J, Grolleau R. [Endocarditis due to *Listeria monocytogenes*]. *Coeur Med Interne* 1970;9:59–67.
- [10] Degeorges M, Heintz C, Valty J, Drouhet E, Acar JF, Leduc G. [Infectious endocarditis due to *Listeria monocytogenes* and *Cephalosporium*]. *Endocardite infectieuse a Listeria monocytogenes et a Cephalosporium*. *Presse Med* 1971;79:1377–80.
- [11] Quiret JC, Bens JL, Lienard J, Laurans G, Orfila J, Lesbre JP. [*Listeria monocytogenes* endocarditis (apropos of a case)]. *Arch Mal Coeur Vaiss* 1972;65:765–75.
- [12] De Soldati L, Alescio AC, Cola HJ. Bacterial endocarditis due to *Listeria monocytogenes*. *Cardiology* 1972;57:172–80.
- [13] Bowmer EJ, McKiel JA, Cockcroft WH, Schmitt N, Rappay DE. *Listeria monocytogenes* infections in Canada. *Can Med Assoc J* 1973;109:125–9 *passim*.
- [14] Leonard A, Raji L, Shapiro FL. Bacterial endocarditis in regularly dialyzed patients. *Kidney Int* 1973;4:407–22.
- [15] Bassan R. Bacterial endocarditis produced by *Listeria monocytogenes*. Case presentation and review of literature. *Am J Clin Pathol* 1975;63:522–7.
- [16] Weinstein GS, Nichols NJ, Rogers MR, Franzone AF, Stertzner SH, Wallsh E. Letter: Endocarditis of aortic valvular prosthesis due to *Listeria monocytogenes*. *Chest* 1976;69:807–8.
- [17] Humbert G, Duval C, Fessard C, Meunier M, Ledoux A. Human *Listeriosis* in France to Day - Study of 824 Cases. 1. *Lyon Med* 1977;237:275–89.
- [18] Clark RA. Bacterial endocarditis caused by *Listeria monocytogenes*. *West J Med* 1977;126:403–5.
- [19] Bayer AS, Chow AW, Guze LB. *Listeria monocytogenes* endocarditis: report of a case and review of the literature. *Am J Med Sci* 1977;273:319–23.
- [20] Kaplan J, Stollenwerk A. *Listeria monocytogenes* endocarditis. *Arch Intern Med* 1977;137:1484.
- [21] Holshouser CA, Ansbacher R, McNitt T, Steele R. Bacterial endocarditis due to *Listeria monocytogenes* in a pregnant diabetic. *Obstet Gynecol* 1978;51:9s–10s.
- [22] Breyer RH, Arnett EN, Spray TL, Roberts WC. Prosthetic-valve endocarditis due to *Listeria monocytogenes*. *Am J Clin Pathol* 1978;69:186–7.

- [23] Pitcher D, Mary D. *Listeria monocytogenes* endocarditis in hypertrophic cardiomyopathy. *Br Med J* 1978;1:961.
- [24] Saravolatz LD, Burch KH, Madhavan T, Quinn EL. Listerial prosthetic valve endocarditis. Successful medical therapy. *JAMA* 1978;240:2186-7.
- [25] Saraiva LR, Montenegro D, Padilha M, Victor EG. [Infectious *Listeria monocytogenes* endocarditis. Apropos of a case]. *Arq Bras Cardiol* 1979;33:193-5.
- [26] Cremades EJ, Bazzino O, Cagide A, Di Marco MC, Liotta D. Reemplazo valvular aortico en la insuficiencia aortica aguda postendocarditis bacteriana: resultados inmediatos y alejados. *Rev Argentina Cardiol* 1980;48:211-7.
- [27] Gelber RH, Borchardt KA, Crull SL. Synergistic therapy for listeria endocarditis: case report. *Mil Med* 1980;145:704.
- [28] Skidmore AG. Listeriosis at Vancouver General Hospital, 1965-79. *Can Med Assoc J* 1981;125:1217-21.
- [29] Winslow DL, Holloway WJ, Scott EG. Listeria sepsis: a report of 27 cases. *infect Dis Rev* 1981;6:187-215.
- [30] Higgins TL, Mallek JA, Slugg PH. *Listeria monocytogenes* endocarditis on a prosthetic heart valve. *South Med J* 1983;76:675-6.
- [31] Davis WR, Taylor JL. *Listeria monocytogenes* prosthetic valve endocarditis. *South Med J* 1983;76:1074.
- [32] Arruda WO, de Souza HA, Cardoso Mde A. [Infectious endocarditis caused by *Listeria monocytogenes* and mycotic aneurysm of the deep femoral artery. Report of a case]. *Arq Bras Cardiol* 1984;43:119-21.
- [33] Pova R, Ferreira C, Korkes H, Smith MR, Novaretti JR, Kasinski N, et al. [Infective *Listeria monocytogenes* endocarditis in a valve prosthesis. Report of a case]. *Arq Bras Cardiol* 1984;42:45-7.
- [34] Sheinman BD, Evans T, Sage R. *Listeria monocytogenes* endocarditis. *Postgrad Med J* 1985;61:51-2.
- [35] Anonymous. Bacteraemia and bacterial meningitis. *Commun Dis Rep* 1985;18.
- [36] Anonymous. Bacteraemia and bacterial meningitis. *Commun Dis Rep* 1986;2.
- [37] Gallagher PG, Amedia CA, Watanakunakorn C. *Listeria monocytogenes* endocarditis in a patient on chronic hemodialysis, successfully treated with vancomycin-gentamicin. *Infection* 1986;14:125-8.
- [38] Anonymous. Bacteraemia and bacterial meningitis. *Commun Dis Rep* 1986;50.
- [39] Alonso J, Revuelta JM, Marce L, Fleitas MG, Duran CM. Successful surgical treatment of a case of *Listeria monocytogenes* endocarditis. *J Cardiovasc Surg (Torino)* 1988;29:140-2.
- [40] Carvajal A, Frederiksen W. Fatal endocarditis due to *Listeria monocytogenes*. *Rev Infect Dis* 1988;10:616-23.
- [41] Jackson RT, Clark WM. *Listeria monocytogenes* endocarditis. *J Tenn Med Assoc* 1988;81:21-2.
- [42] Riancho JA, Echevarria S, Napal J, Martin Duran R, Gonzalez Macias J. Endocarditis due to *Listeria monocytogenes* and human immunodeficiency virus infection. *Am J Med* 1988;85:737.
- [43] Aparici M, Saenz de Buruaga JD, Castello R, Hidalgo R, Peteiro J, Frades M, et al. [*Listeria monocytogenes* endocarditis on a Hancock bioprosthesis]. *Rev Esp Cardiol* 1988;41:440-2.
- [44] Baddour LM. Listerial endocarditis following coronary artery bypass surgery. *Rev Infect Dis* 1989;11:669.
- [45] Rao N. *Listeria* prosthetic valve endocarditis. *J Thorac Cardiovasc Surg* 1989;98:303-4.

- [46] Lazanas M, Perronne C, Leport C, Kitzis M, Morgant C, Vahanian A. [Listeria monocytogenes endocarditis in a patient with mechanical valve prosthesis]. *Presse Med* 1990;19:571.
- [47] Ochoteco A, Aguado Garcia JM, Mazarrasa C, Martin Duran R, Poveda JJ, Berrazueta R, et al. [Mitro-aortic endocarditis caused by Listeria monocytogenes]. *Rev Esp Cardiol* 1990;43:123-6.
- [48] Berenguer J, Solera J, Diaz MD, Moreno S, Lopez-Herce JA, Bouza E. Listeriosis in patients infected with human immunodeficiency virus. *Rev Infect Dis* 1991;13:115-9.
- [49] Segura J, Anguita M, Vivancos R, Franco M, Romo E, Suarez de Lezo J, et al. [Listeria monocytogenes endocarditis in a patient with mitral prosthesis, left auricular thrombus and adenocarcinoma of the colon]. *Rev Esp Cardiol* 1992;45:483-5.
- [50] Lifshitz A, Fadilah R, Sidi Y, Pinkhas J. Listeria monocytogenes endocarditis in a patient with a prosthetic aortic valve. *Isr J Med Sci* 1993;29:49-50.
- [51] Hadorn K, Hachler H, Schaffner A, Kayser FH. Genetic characterization of plasmid-encoded multiple antibiotic resistance in a strain of Listeria monocytogenes causing endocarditis. *Eur J Clin Microbiol Infect Dis* 1993;12:928-37.
- [52] Speeleveld E, Muyldermans L, Van den Bruel A, Dhondt E, Gordts B, Van Landuyt HW. Prosthetic valve endocarditis due to Listeria monocytogenes. A case report with review of the literature. *Acta Clin Belg* 1994;49:95-8.
- [53] Cruz JM, Fernandez R, Martinez R, Isusi A. [Endocarditis caused by Listeria monocytogenes in a valve prosthesis]. *Enferm Infecc Microbiol Clin* 1994;12:221-2.
- [54] Castro Cabezas M, Cramer MJ, de Jongh BM, de Maat CE. Listeria monocytogenes endocarditis in a patient with an aortic prosthetic valve. *Neth J Med* 1996;48:15-7.
- [55] Spyrou N, Anderson M, Foale R. Listeria endocarditis: current management and patient outcome--world literature review. *Heart* 1997;77:380-3.
- [56] Manso C, Rivas I, Peraire J, Vidal F, Richart C. Fatal Listeria meningitis, endocarditis and pericarditis in a patient with haemochromatosis. *Scand J Infect Dis* 1997;29:308-9.
- [57] de Miguel JM, Pastor L, Parras F, Javier Cabrera F, Teigell L, Prieto A, et al. [Endocarditis caused by Listeria monocytogenes on a prosthetic valve: presentation of a case and review of the bibliography]. *Enferm Infecc Microbiol Clin* 1998;16:151-2.
- [58] Johnston PW, Trouton TG. Dietary precautions and listeria endocarditis? *Heart* 1998;79:206.
- [59] Avery RK, Barnes DS, Teran JC, Wiedemann HP, Hall G, Wacker T, et al. Listeria monocytogenes tricuspid valve endocarditis with septic pulmonary emboli in a liver transplant recipient. *Transpl Infect Dis* 1999;1:284-7.
- [60] Hood S, Baxter RH. Listeria endocarditis causing aortic root abscess and a fistula to the left atrium. *Scott Med J* 1999;44:117-8.
- [61] Torres L, Blasco M, Marco ML, Ruiz MA, Uriel B, Revillo P. [Listeria monocytogenes endocarditis of a prosthetic valve]. *Rev Esp Cardiol* 2000;53:300.
- [62] Benes J, Viechova J, Kabelkova M, Horova B. Listerial endocarditis in a penicillin-allergic woman successfully treated with a combination of 4 drugs. *Scand J Infect Dis* 2002;34:383-4.
- [63] Candela L. Caring for a patient with Listeria endocarditis: use of antibiotic desensitization. *Crit Care Nurse* 2002;22:38-43.
- [64] Makaryus AN, Yang R, Cohen R, Rosman D, Mangion J, Kort S. A rare case of Listeria monocytogenes presenting as prosthetic valve bacterial endocarditis and aortic root abscess. *Echocardiography* 2004;21:423-7.

- [65] Fernandez Guerrero ML, Rivas P, Rabago R, Nunez A, de Gorgolas M, Martinell J. Prosthetic valve endocarditis due to *Listeria monocytogenes*. Report of two cases and reviews. *Int J Infect Dis* 2004;8:97–102.
- [66] Ono T, Moriyama A, Mitsuo K, Aikawa J. [Endocarditis due to *Listeria monocytogenes* associated with aortic stenosis]. *Nihon Naika Gakkai Zasshi* 2005;94:2609–12.
- [67] Munoz P, Ferreira L, Marin M, Rodriguez-Creixems M, Bouza E, Garcia-Fernandez MA, GAME Study Group. First report of *Listeria monocytogenes* endocarditis treated with linezolid. *Int J Antimicrob Agents* 2006;28:480–1.
- [68] Llanwarne N, Badic B, Delugeau V, Landen S. Spontaneous splenic rupture associated with *Listeria* endocarditis. *Am J Emerg Med* 2007;25:1086.e3–5.
- [69] Karavidas A, Halapas A, Zacharoulis A, Matsakas E, Zacharoulis A. A subacute bacterial endocarditis in a patient with aortic prosthetic valve due to *Listeria monocytogenes* presenting with perivalvular leak. *Int J Cardiol* 2007;118:e106–7.
- [70] Kida K, Osada N, Isahaya K, Mikami T, Yoneyama K, Kongoji K, et al. *Listeria* endocarditis with acute thoracoabdominal aortic dissection. *Intern Med* 2007;46:1209–12.
- [71] Antolin J, Gutierrez A, Segoviano R, Lopez R, Ciguenza R. Endocarditis due to *Listeria*: description of two cases and review of the literature. *Eur J Intern Med* 2008;19:295–6.
- [72] Lindholm AC. [Prosthetic valve *Listeria* endocarditis caused septic cerebral embolism]. *Lakartidningen* 2008;105:2670–1.
- [73] Pocar M, Passolunghi D, Moneta A, Donatelli F. Fulminant prosthetic valve endocarditis caused by *Listeria monocytogenes*. *Eur J Cardiothorac Surg* 2009;36:1077.
- [74] Adler A, Fimbres A, Marcinak J, Johnson A, Zheng X, Hasegawa S, et al. Inflammatory pseudotumor of the heart caused by *Listeria monocytogenes* infection. *J Infect* 2009;58:161–3.
- [75] Summa C, Walker SA. Endocarditis due to *Listeria monocytogenes* in an academic teaching hospital: case report. *Can J Hosp Pharm* 2010;63:312–4.
- [76] Kelesidis T, Salhotra A, Fleisher J, Uslan DZ. *Listeria* endocarditis in a patient with psoriatic arthritis on infliximab: are biologic agents as treatment for inflammatory arthritis increasing the incidence of *Listeria* infections? *J Infect* 2010;60:386–96.
- [77] Di Cori A, Spontoni P, Bongiorno MG. Left ventricular outflow tract to left atrium fistula due to non-valve *Listeria monocytogenes* endocarditis. *Eur Heart J* 2012;33:2235.
- [78] Fuertes A, Goenaga MA, Ibarguren M, Perez N, Elola M. [*Listeria monocytogenes* endocarditis: two case reports with poor outcome]. *Rev Esp Quimioter* 2012;25:169–70.
- [79] Berthelot E, Voicu S, de Menthon M, Logeart D, Mahr A, Nataf P, et al. Unusual pseudotumoral right atrial involvement in *Listeria monocytogenes* septicemia. *Circulation* 2012;126:e66–8.
- [80] Marin A, Lustig N, Cruz R, Cordova S. [Infective endocarditis caused by *Listeria monocytogenes*: review of the literature and a case report]. *Rev Chilena Infectol* 2013;30:436–40.
- [81] Uehara Yonekawa A, Iwasaka S, Nakamura H, Fukata M, Kadowaki M, Uchida Y, et al. Infective endocarditis caused by *Listeria monocytogenes* forming a pseudotumor. *Intern Med* 2014;53:1029–32.
- [82] Frydland M, Bundgaard H, Moser C, Dahlstrom CG, Ihlemann N. [Sausage-related *Listeria monocytogenes* infection]. *Ugeskr Laeger* 2014;176.

- [83] Tainta M, de la Riva P, Gonzalez F, Marti-Masso JF, Goenaga MA. [Rhombencephalitis and endocarditis caused by *Listeria monocytogenes*: an unreported association]. *Rev Neurol* 2016;63:46–8.
- [84] Jyothidasan A, Noe S, Calkins JB Jr. Listerial prosthetic valve endocarditis in a patient with congenitally corrected transposition of the great vessels. *Int J Cardiol* 2016;223:433–5.
- [85] Gallego-Flores A, Carrasco-Cubero C, Aznar-Sanchez JJ, Chamizo-Carmona E. Ankle arthritis and nail clubbing as a form of presentation of *Listeria monocytogenes* endocarditis. *Reumatol Clin* 2016;12:178–9.
- [86] Garcia-Granja PE, Lopez J, Vilacosta I, Olmos C, Sarria C, San Roman JA. Infective endocarditis due to *Listeria monocytogenes*: a report of 4 patients. *Rev Esp Cardiol (Engl Ed)* 2016;69:700–2.
- [87] Hasan T, Chik W, Chen S, Kok J. Successful treatment of *Listeria monocytogenes* prosthetic valve endocarditis using rifampicin and benzylpenicillin in combination with valve replacement. *JMM Case Rep* 2017;4:e005085.